

Morphological study of the palatine mucosa in the type 2 diabetes mellitus model rat

Keisuke Akai, Mamoru Uemura and Fumihiko Suwa

Department of Anatomy, Osaka Dental University, 8-1 Kuzuhahanazono-cho, Hirakata-shi, Osaka 573-1121, Japan

We studied morphological differences in the palatine mucosa of two kinds of rats : the spontaneous type 2 diabetes mellitus (DM) rat (n = 6) and the normal Wistar rat (n = 6). Image analyses, performed on light micrographs of hematoxylin-eosin stained specimens, were used to compare the thickness of the keratinized, granular, prickle and basal layers in the mucosal epithelium. Further, the cell population of the granular and prickle layers and the thickness of the connective tissue beneath the mucosal epithelium were examined. The diameter of the capillaries in the palatine mucosa was determined by image analysis of scanning electron micrographs of microvascular corrosion cast specimens. We found that the keratinized and granular layers were significantly thicker in DM than in normal rats ($p < 0.01$; both layers). Moreover, the cell population of the granular layer was significantly greater in DM than in normal rats ($p < 0.01$). In contrast, the thickness of the connective tissue beneath the mucosal epithelium, and the diameter of the capillaries were significantly smaller in the DM than in normal rats ($p < 0.01$). Our results indicate that hyperglycemia associated with type 2 DM causes hypertrophy of the keratinized and granular layers in the mucosal epithelium, atrophy of connective tissue beneath the mucosal epithelium, and microangiopathy of the capillaries of the palatine mucosa in the DM rat. (*J Osaka Dent Univ* 2013 ; **47 : 185–194)**

Key words : Type 2 diabetes mellitus ; Palatine mucosa ; Microvascular corrosion cast ; GK rats

INTRODUCTION

Hyperglycemia is thought to cause hypertrophy of the mucosal epithelium, atrophy of the connective tissue beneath the mucosal epithelium, and diabetic microangiopathy of the capillaries in the spontaneous type 2 diabetes mellitus (DM) rat.¹ To our knowledge, no previous studies have investigated the mucosal epithelium, the connective tissue beneath the mucosal epithelium, or the capillaries of the palatine mucosa in the DM rat.

To contribute to knowledge in this field, we investigated the mucosal epithelium (the keratinized, granular, prickle and basal layers), the connective tissue beneath the mucosal epithelium, and capillaries of the palatine mucosa in the DM rat. We then compared morphological differences between normal (N) and DM rats. In addition, we thought that morphological changes might occur in other organs (the palatal gin-

giva of the maxillary first molar and the lingual gingiva of the mandibular first molar), and we compared morphological differences of other oral organs between N and DM rats.^{1–4}

MATERIALS AND METHODS

Experimental animals

Twelve experimental animals (Shimizu Laboratory Supplies, Kyoto, Japan) were used in this study. Six 8-week-old male Wistar rats weighing 240.0 ± 11.6 g comprised the N group, and six 8-week-old male Goto-Kakizaki⁵ (GK) rats weighing 204.4 ± 12.6 g were in the DM group. Three rats from each group were used to prepare sections for the hematoxylin-eosin stained specimens, and the remaining three rats from each group were used for microvascular corrosion cast specimens. This experiment was approved by the Osaka Dental University Animal Research Committee (approval numbers 08–02016, 09

–02009 and 10–02007) and complied with the guidelines for animal experiments.

Methods

Preparation and sacrifice of the rats

All rats were fasted for 20 hours and then weighed. Rats were anaesthetized with isoflurane inhalation anesthesia (Forane[®], Abbott Japan, Tokyo, Japan), and then injected intraperitoneally with heparin sodium (Novo Heparin Injection 5000[®], Mochida Pharmaceutical, Tokyo, Japan). We euthanized the animals by means of intraperitoneal injection of excess sodium pentobarbital (Nembutal[®], Dainippon Sumitomo Pharma, Osaka, Japan) 30 minutes after injecting with heparin sodium. The thorax of each rat was opened, and blood was collected from the left ventricle with a 5 mL Terumo Syringe[®] (Terumo, Tokyo, Japan) for measurement of fasting blood glucose and hemoglobin A1c (HbA1c) levels as described below. We inserted a cannula through the left ventricle into the ascending aorta and then infused physiological saline into the ascending aorta. Specimens were collected from all rats after blood collection from the right atrial auricle. Specimens were prepared according to the methods described below.

Measurement of fasting blood glucose levels

Fasting blood glucose levels were measured in rat serum samples with the HK-G-6-PDH (Quick Auto Neo GLU-HK, Sino Test, Tokyo, Japan)⁵ according to instructions of the manufacturer. Sera were obtained by centrifugal separation of the collected blood samples. In this study, the DM group with 6 GK rats was expected to have fasting blood glucose levels of greater than 150 mg/dL, as reported by Goto and Kakizaki.⁵

Measurement of HbA1c levels

HbA1c levels were measured by means of the latex agglutination (RAPIDIA[®], Auto HbA1c-L, Fujirebio, Tokyo, Japan)⁷ according to National Glycohemoglobin Standardization Program guidelines.

Preparation of hematoxylin-eosin stained specimens

Specimens from three rats of each group were used to prepare sections of the palatine mucosa. Physiological saline solution containing 4% (w/v) paraformaldehyde (Formaldehyde Solution[®], Kishida Chemical, Osaka, Japan) was injected into the ascending aorta. Figures 1 A and B show a cut section of a specimen. Line a was drawn at the proximal margin of the bilateral maxillary first molars, and line b was drawn at the distal margin. Cutting was done with a band saw (EXAKT Diamond Band Saw 300, EXAKT, Germany). The palatine mucosa, osseous tissue, and maxillary first molars were removed as one piece, fixed by soaking in physiological saline solution containing 4% (w/v) paraformaldehyde, and kept at 4°C for 24 hours. These specimens were decalcified in 10% (w/v) ethylenediaminetetraacetic acid disodium salt (EDTA) solution (Kishida Chemical) for 10 days using a microwave rapid sample processor (ML-77, Azumaya, Tokyo, Japan). The specimens were washed and then frozen at –20°C. Serial frontal sections of 20- μ m thick were sliced with a cryostat (HM 500-OM, Carl Zeiss Japan, Tokyo, Japan) from the area of the square frame shown in Fig. 1 B. These sections were stained with hematoxylin-eosin solution. Five sections that did not project into the palatine lamella were randomly selected from each group, and used to investigate the histological form of the pala-

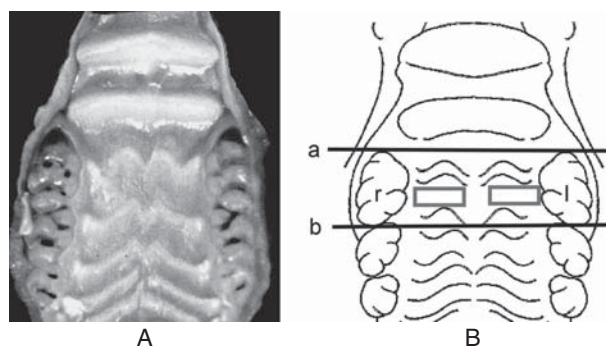


Fig. 1 Macroscopic photograph (A), and schematic illustration (B) of the palatine mucosa.

Line a is at the proximal margin of the right (r) and left (l) maxillary first molars. Line b is at the distal margin of r and l. The square frames show the areas observed by light and scanning electron microscopy.

tine mucosa. Digital images of the stained sections were taken using a light microscope equipped with a digital camera (BZ-9000[®], Keyence, Osaka, Japan).

Preparation of microvascular corrosion cast specimens

Three rats from each group were used to investigate the microvascular architecture of the palatine mucosa. Polymerization inhibitor (hydroquinone) was kept in commercial methyl methacrylate (Acrylic Ester M[®], MMA, Mitsubishi Rayon, Tokyo, Japan). Hydroquinone was removed using the sodium hydroxide solution method according to the description of Polymer Syntheses.⁸ One liter commercial methyl methacrylate was placed in a three liter beaker, to which was added 1 liter of 0.5% (w/v) sodium hydroxide solution. This mixture was then stirred for 5 minutes with a magnetic stirrer (HVE-S, As One, Osaka, Japan). After stirring, the liquid was placed in a three liter separation funnel (Funnel Separatory Globe with Teflon Stopcock, Sanyo, Tokyo, Japan), and left to settle. The sodium hydroxide solution (an aqueous solution that became brown with the sodium salt of hydroquinone) and the methyl methacrylate (oil) were separated. The brown-colored aqueous solution was removed with the use of the separation funnel. This procedure was repeated three times. We confirmed that the brown-colored aqueous solution became transparent.

One liter of the remaining oil was placed in the three liter beaker. In addition, to adjust the neutrality, one liter of the distilled water was placed in the oil and then stirred for 5 minutes with the magnetic stirrer. This procedure was repeated three times. We checked the neutrality with a pH meter (BASIC pH meter, Denver Instrument GmbH, Göttingen, Germany). Finally, to remove any remaining water, 100 g anhydrous magnesium sulfate (Nacalai Tesque, Kyoto, Japan) was added to the oil. We filtered the solution to remove the anhydrous sodium sulfate. The commercial methyl methacrylate (liquid monomer), which removed the hydroquinone, was moved to a dark glass bottle, and maintained at 4°C.

We prepared a low-viscosity acrylic resin by mixing polymethyl methacrylate (solid polymer; Sigma-

Aldrich Japan, Tokyo, Japan) and liquid monomer at a 1 : 9 ratio. High-viscosity acrylic resin was prepared from a 3 : 7 ratio of polymer to monomer. We added 0.5% polymerization promoter (benzoyl peroxide, Kishida Chemical), 5% plasticizer (di-n-butyl phthalate, Kishida Chemical), pigment (Cromophtal Red, Ciba Japan, Tokyo, Japan), and 0.5% polymerization initiator (N,N-dimethylaniline, Kishida Chemical) to these mixtures to initiate polymerization. First, we injected the low-viscosity acrylic resin (100 mL, 5 mL/minute) into the ascending aorta of rats using a precision syringe pump (KDS 200, Muromachi Kikai, Tokyo, Japan). We then used the same pump to inject 10 mL of high-viscosity acrylic resin at 1 mL/minute into the aorta. The injected carcasses were allowed to polymerize at 40°C for 24 hours in a water bath (Thermo Regulator, CTR-320, Iwaki, Tokyo, Japan).

Specimens were collected from the polymerized animals. The palatine mucosa, osseous tissue, and maxillary first molars were removed as one piece using a band saw. Thereafter, the soft tissues were removed by soaking the specimens in a 12% low-salt sodium hypochlorite solution (Hypochlorite soda[®], Fukae Trading, Osaka, Japan) for 24 hours at 40°C. The specimens were then washed in an ultrasonic cleaner (UT-105 HS, Sharp, Osaka, Japan) with hot (40°C) running water. Each specimen was air-dried, mounted on a metal stage with silver paste (Dotite[®], Fujikura Kasei, Tochigi, Japan), and coated with gold using an ion-sputtering coating device (JFC-1500, JEOL, Tokyo, Japan). Digital images of the microvascular architecture of the palatine mucosa were obtained by scanning electron microscope (JSM-5500, JEOL) at an acceleration voltage of 5 kV and a working distance of 40 mm. The observed area of the square frame is shown in Fig. 1 B.

Image and statistical analyses

Digital images of hematoxylin-eosin stained sections were used to measure the tissue layer thickness of the keratinized, granular, prickle and basal layers, and the cell population of the granular and prickle layers. We used BZ-2 Analyzer measurement software (Keyence) based on the methods described below. We used Image-Pro measurement software (Image-Pro

Plus® 5.0 J, Nippon Roper, Tokyo, Japan) to measure the diameter of the capillaries on the digital images of the microvascular corrosion cast specimens. The methods are described in detail below. Measurements are represented as the mean \pm standard deviation (SD), and Student's t-test was used to test for differences between the two groups, with significance set at $p < 0.01$.

Thickness of the mucosal epithelium

We arbitrarily chose five epithelial processes among the digital images. The most inferior point of each epithelial process was assumed to be "z." A perpendicular line (u) was drawn from "z" to the tangent on the surface of the palatine mucosa. The intersection of line u and the uppermost surface of the keratinized layer was assumed to be "v." The distance from "v" to "z" was taken as the thickness of the mucosal epithelium (e) (Figs. 2 A and B).

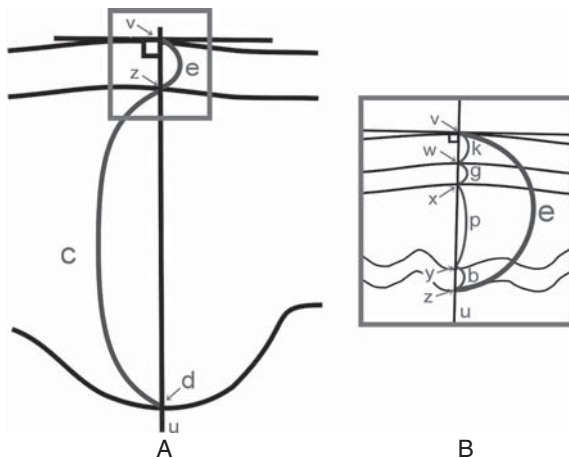


Fig. 2 Schematic diagram of the palatine mucosa (A) and enlargement of the square frame (B).

e : Thickness of the mucosal epithelium, c : Thickness of the connective tissue beneath the mucosal epithelium, z : The most inferior point of the epithelial process, u : A perpendicular line drawn from z to the line tangent to the surface of the palatine mucosa, d : The intersection of line u and the deepest part of the palatine sulcus, v : Intersection of line u and the surface of the keratinized layer, k : Thickness of the keratinized layer, g : Thickness of the granular layer, p : Thickness of the prickle layer, b : Thickness of the basal layer, w : Intersection of the line u and the deepest point of the keratinized layer, x : Intersection of the line u and the deepest point of the granular layer, y : Intersection of the line u and the deepest point of the prickle layer.

Thickness of the keratinized layer

The intersection of line u and the deepest point of the keratinized layer was defined as "w." The distance from "v" to "w" was taken as the thickness of the keratinized layer (k) (Fig. 2 B).

Thickness of the granular layer

The intersection of line u and the deepest point of the granular layer was defined as "x." The distance from "w" to "x" was taken as the thickness of the granular layer (g) (Fig. 2 B).

Thickness of the prickle layer

The intersection of line u and the deepest point of the prickle layer was defined as "y." The distance from "x" to "y" was taken as the thickness of the prickle layer (p) (Fig. 2 B).

Thickness of the basal layer

The distance from "y" to "z" was taken as the thickness of the basal layer (b) (Fig. 2 B).

Cell population of the granular and prickle layers

The number of cells in the granular and prickle layers on line u were counted (Fig. 2 B).

Thickness of connective tissue beneath the mucosal epithelium

The intersection of line u and the deepest part of palatine sulcus was defined as "d." The distance from "d" to "z" was taken as the thickness of connective tissue beneath the mucosal epithelium (c) (Fig. 2 A).

Diameter of the capillaries

The diameter of the capillaries, which were in the connective tissue beneath the mucosal epithelium of the palatine mucosa, was measured using the microvascular corrosion cast.

RESULTS

Fasting blood glucose levels

Fasting glucose levels were 113.2 ± 20.9 mg/dL and 207.8 ± 53.4 mg/dL in the N and DM groups, respectively. The levels were found to be significantly greater in the DM group than in the N group ($p < 0.01$, Fig.

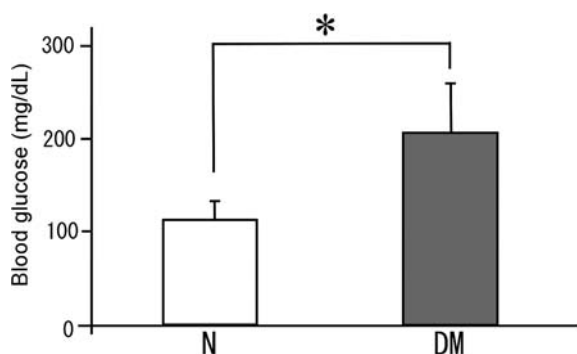


Fig. 3 Comparison of fasting blood glucose levels in the normal (N) and diabetes mellitus (DM) groups (* $p < 0.01$).

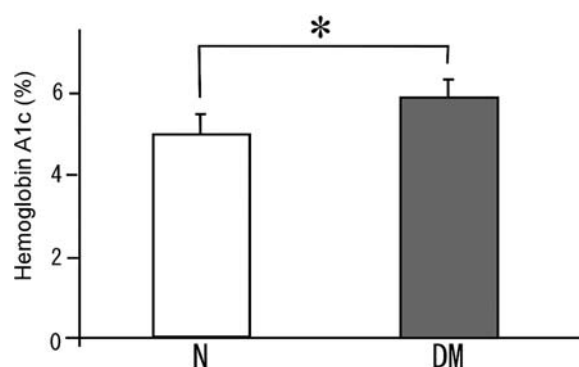


Fig. 4 Comparison of hemoglobin A1c levels in the N and DM groups (* $p < 0.01$).

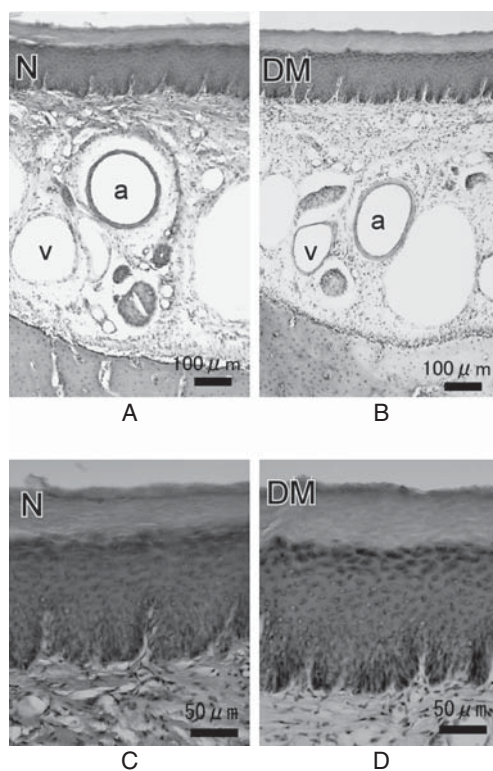


Fig. 5 Light micrographs of hematoxylin-eosin stained specimens in the normal (N) group at lower magnification (A) and higher magnification (C), and in the diabetes mellitus (DM) group at lower magnification (B) and higher magnification (D). a : Greater palatine artery v : Greater palatine vein.

3).

Hemoglobin A1c levels

The HbA1c levels were $5.0\% \pm 0.5\%$ and $5.9\% \pm 0.4\%$ in the N and DM groups, respectively. The levels were found to be significantly greater in the DM group than in the N group ($p < 0.01$, Fig. 4).

Findings in the hematoxylin-eosin stained specimens

We could observe or discern the following in both the N and the DM rats : 1) the mucosal epithelium (stratified squamous epithelium) and the connective tissue beneath the mucosal layer ; 2) the keratinized, granular, prickle and basal layers ; 3) the anucleate cells (stained only with eosin) in the keratinized layer ; 4) hematoxylin-stained granular cells, including keratohyalin granules, in the granular layer ; 5) cells with intercellular bridges in the prickle layer ; 6) the single

layer of columnar cells in the basal layer ; and 7) the greater palatine artery and vein (Figs. 5 A, B, C and D).

Findings in the microvascular corrosion cast specimens

In both the N and DM groups, the microvascular architecture of the palatine mucosa served as the capillary networks that formed the reticulation in a tortoise shell pattern. However, the reticulation of the capillary networks in the N group was smaller than that in the DM group (Figs. 6 A and B).

Image and statistical analyses

Thickness of the mucosal epithelium

The average thickness of the mucosal epithelium was $146.5 \pm 22.0 \mu\text{m}$ and $168.0 \pm 10.9 \mu\text{m}$ in the N and DM groups, respectively. These values were significantly greater in the DM group than in the N group (p

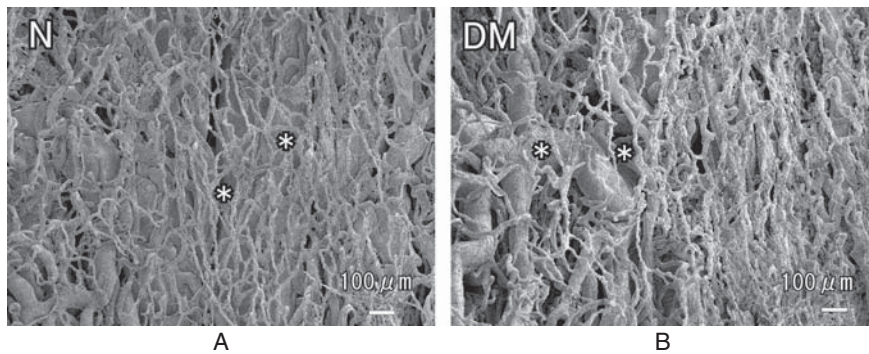


Fig. 6 Scanning electron micrographs of microvascular corrosion cast specimens in the N (A) and the DM (B) groups (* capillary network).

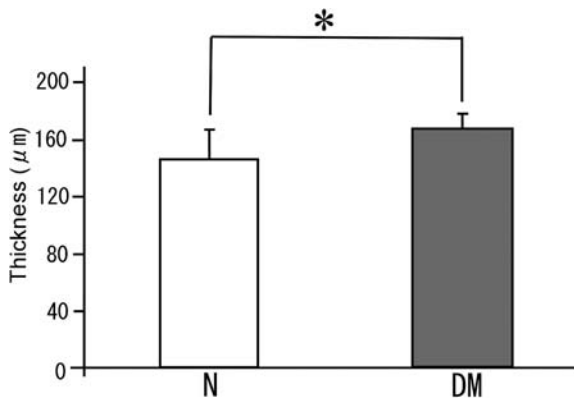


Fig. 7 Comparison of the thickness of the mucosal epithelium in the N and DM groups (* $p < 0.01$).

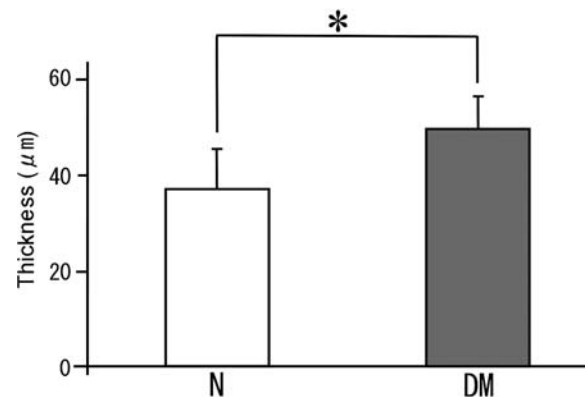


Fig. 8 Comparison of the thickness of the keratinized layer in the N and DM groups (* $p < 0.01$).

< 0.01 , Fig. 7).

Thickness of the keratinized layer

The average thickness of the keratinized layer was $37.2 \pm 8.5 \mu\text{m}$ and $50.0 \pm 6.7 \mu\text{m}$ in the N and DM groups, respectively. These values were significantly greater in the DM group than in the N group ($p < 0.01$, Fig. 8).

Thickness of the granular layer

The average thickness of the granular layer was $21.8 \pm 5.3 \mu\text{m}$ and $34.5 \pm 6.9 \mu\text{m}$ in the N and DM groups, respectively. These values were significantly greater in the DM group than in the N group ($p < 0.01$, Fig. 9).

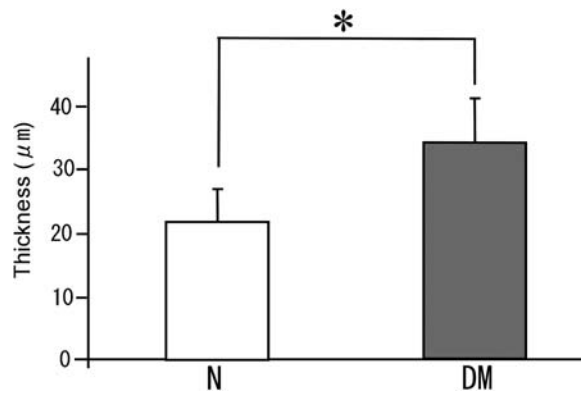


Fig. 9 Comparison of the thickness of the granular layer in the N and DM groups (* $p < 0.01$).

Thickness of the prickly layer

The average thickness of the prickly layer was 69.5

$\pm 13.2 \mu\text{m}$ and $64.7 \pm 10.3 \mu\text{m}$ in the N and DM groups, respectively. There was no significant difference between two groups ($p > 0.01$, Fig. 10).

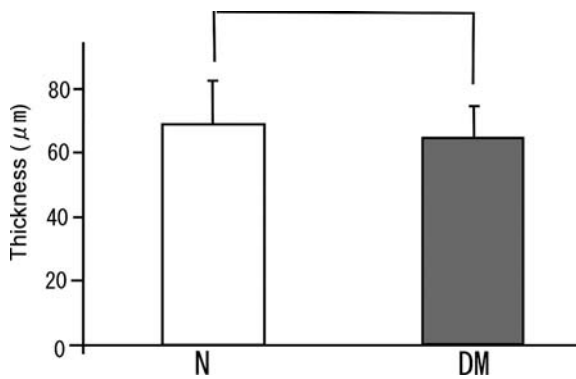


Fig. 10 Comparison of the thickness of the prickle layer in the N and DM groups.

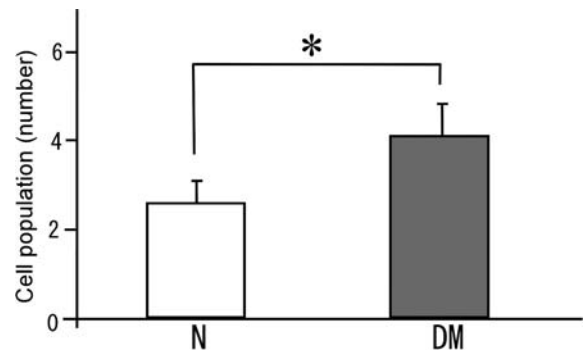


Fig. 12 Comparison of the number of cells in the granular layer on line u in the N and DM groups (* $p < 0.01$).

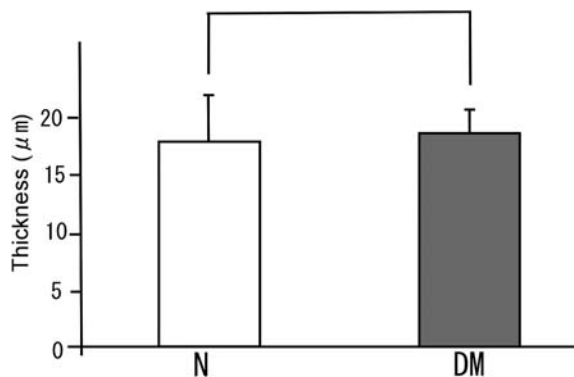


Fig. 11 Comparison of the thickness of the basal layer in the N and DM groups.

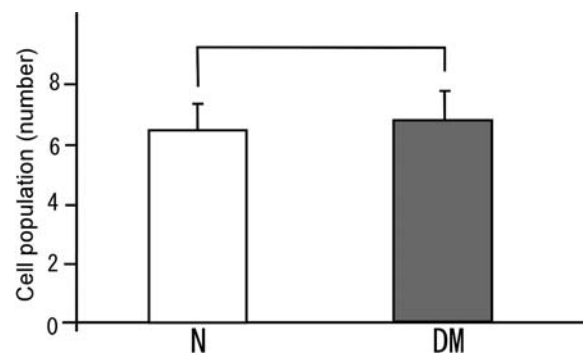


Fig. 13 Comparison of the number of cells in the prickle layer on line u in the N and DM groups.

Thickness of the basal layer

The average thickness of the basal layer was $18.1 \pm 3.9 \mu\text{m}$ and $18.7 \pm 2.1 \mu\text{m}$ in the N and DM groups, respectively. There was no significant difference between two groups ($p > 0.01$, Fig. 11).

Cell population of the granular layer

The cell populations of the granular layer were 2.6 ± 0.5 and 4.1 ± 0.7 in the N and DM groups, respectively. These values were significantly greater in the DM group than in the N group ($p < 0.01$, Fig. 12).

Cell population of the prickle layer

The cell populations of the prickle layer were 6.3 ± 1.1 and 6.8 ± 0.7 in the N and DM groups, respectively. There was no significant difference between two groups ($p > 0.01$, Fig. 13).

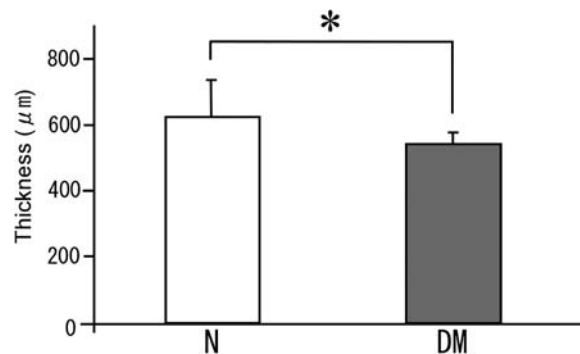


Fig. 14 Comparison of the thickness of the connective tissue beneath the mucosal epithelium in the N and DM groups (* $p < 0.01$).

Thickness of connective tissue beneath the mucosal epithelium

The thickness of the connective tissue beneath the mucosal epithelium was $628.9 \pm 110.0 \mu\text{m}$ and 546.6

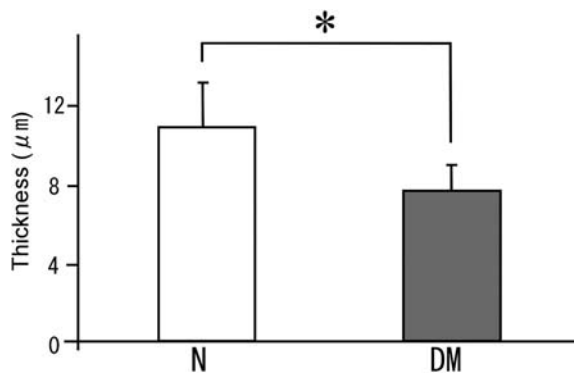


Fig. 15 Comparison of the diameter of capillaries in the N and DM groups (* $p < 0.01$).

$\pm 32.6 \mu\text{m}$ in the N and DM groups, respectively. These values were significantly lower in the DM group than in the N group ($p < 0.01$, Fig. 14).

Average diameter of capillaries

The average diameter of the capillaries were $11.0 \pm 2.2 \mu\text{m}$ and $7.6 \pm 1.4 \mu\text{m}$ in the N and DM groups, respectively. These values were significantly lower in the DM group than in the N group ($p < 0.01$, Fig. 15).

DISCUSSION

Hyperglycemia is common among type 2 DM patients, and is associated with changes in the oral mucosa. There are many people with type 2 DM in the adult population of Japan, and it would be valuable to know how the mucosal epithelium and the connective tissue beneath the mucosal epithelium are affected in these patients because this may influence dental procedures. To gain knowledge on the consequences of hyperglycemia on oral mucosa, we designed a pre-clinical study, using the DM rat, to ascertain whether hyperglycemia is associated with changes in the palatine mucosa. Our results clearly showed that hyperglycemia significantly affects the palatine mucosa in a rat model.

We compared the N rats with the GK rats, investigating morphological differences in the mucosal epithelium, the connective tissue beneath the mucosal epithelium, and the capillaries in the palatine mucosa. The palatine mucosa was compared with the palatal gingiva of the maxillary first molar¹ and the lin-

gual gingiva of the mandibular first molar in GK rats using previously reported studies.²⁻⁴

Keratinized layer

We found that in DM rats, the keratinized layer was about 1.3 times thicker than in the N rats. We propose that in DM, the keratinized layer becomes thick because Ca^{2+} -induced differentiation in the presence of high glucose concentrations is associated with an enhanced expression of keratin 1. Keratinocytes maintained in low (2 mmol/L) glucose levels are small and organized, whereas those maintained at high (20 mmol/L) glucose concentrations are larger and flattened, and lose some of their intercellular orientation (*in vitro*).⁹ Therefore, we think that the keratinized layer of GK rats became thicker because of increased keratin in the keratinocytes, and increased granular cells in the subsequent layer.

Previous studies have reported that the keratinized layer of the palatal gingiva of the maxillary first molar was about 1.9 times thicker in GK rats than in the N subjects.¹ When considering these results, we suggest that this occurs because of progressive hypertrophy of the keratinized layer of the palatal gingiva of the maxillary first molar.

Granular layer

The granular layer was about 1.6 times thicker and the cell population was about 1.6 times greater in the DM than in the N rats. It is known that the proliferation rate of oral epithelial cells *in vitro* increases in the presence of high glucose concentrations.¹⁰ It is, therefore, plausible that the granular layer in DM rats thickened because the cell population of granular cells increased. We compared the thickness of the granular layer of the palatine mucosa with that of the palatal gingiva of the maxillary first molar. We found that the thickness of the granular layer of the palatine mucosa was about 1.6 times thicker in the DM than in the N rats. It was previously reported that the granular layer of the palatal gingiva of the maxillary first molar was about 2.3 times thicker in the DM than in the N rats.¹ Therefore, we confirmed that hypertrophy of the granular layer of the palatal gingiva of the maxillary first molar was greater than that of the palatine mu-

cosa in GK rat.

Prickle layer

Previous studies reported that the prickle layer of the palatal gingiva of the maxillary first molar is about 1.6 times thicker and the cell population about 1.6 times larger in the DM group than in the N group¹ It has been suggested that the effect of hyperglycemia is morphologically different in the prickle layer of the palatine mucosa compared with the palatal gingiva of the maxillary first molar in the GK rat. We could not find significant differences in the thickness and the cell population of the prickle layer between the N and DM groups in our study.

Basal layer

A single layer of basal cells could be seen in both N and DM rats, and there was no significant difference in thickness of this layer between the two groups. Similar results were previously reported,² and earlier studies found that there are no morphological differences between the basal layers of the palatal gingiva of the maxillary first molar and the palatine mucosa in DM GK rats. We, therefore, think that hyperglycemia caused hypertrophy of the keratinized and granular layers of the palatine mucosa in our group of DM rats.

Combined layers

Previous studies showed that the mucosal epithelium of the palatal gingiva of the maxillary first molar is about 1.6 times thicker in DM rats than in N rats.¹ In our study, the mucosal epithelium of the palatine mucosa in the DM rats was about 1.1 times thicker than in the N rats. From our results, it is clear that hyperglycemia caused hypertrophy of both the mucosal epithelium of the palatal gingiva of the maxillary first molar and the palatine mucosa. This resulted in hypertrophy of the mucosal epithelium of the palatal gingiva of the maxillary first molar.

It was previously reported that the mucosal epithelium of the lingual gingiva of the mandibular first molar in the GK rats was thinner than in N rats.² This is an interesting observation as it suggests that the hyperglycemic effect is different in the mucosal epithelium of

the palatine mucosa and the palatal gingiva of the corresponding first molars as compared with the lingual gingiva of the corresponding first molars.

Connective tissue beneath the mucosal epithelium

Because the development of the connective tissue papillae beneath the mucosal epithelium of the palatine mucosa in the square frame of the palatine mucosa (Fig. 1 B) was poor in both groups, we were not able to measure the cross-sectional area and the height of the connective tissue papillae. Therefore, we opted to measure the thickness of the connective tissue beneath the mucosal epithelium. It was about 0.7 times thinner in the DM group than in the N group. A previous study with GK rats reported that hyperglycemia causes atrophic changes in the connective tissue papillae of the lingual gingiva of the mandibular first molar.⁴ In addition, dermal fibroblast proliferation was suppressed in GK rats when the cells were cultured in media that contained a high glucose content *in vitro*.¹¹ We propose that the thickness of the connective tissue beneath the mucosal epithelium of the palatine mucosa in the GK rats became narrow because hyperglycemia suppresses the proliferation of fibroblast cells and leads to atrophic changes.

Previous studies found that the cross-sectional area of connective tissue beneath the mucosal epithelium of the palatal gingiva of the maxillary first molar is about 0.5 times smaller in the DM group than in N subjects.² In addition, the thickness and the cross-sectional area of connective tissue of the lingual gingiva of the mandibular first molar was shown to be smaller in the DM group than in the N group.⁴ Therefore, we think that hyperglycemia caused the atrophy in our DM rats, regardless of the region of the oral mucosa.

Capillaries

We were not able to see whether a capillary loop existed in connective tissue papillae, because the development of the connective tissue papillae beneath the mucosal epithelium of the palatine mucosa was poor in the part of the square frame that we used for specimens of the palatine mucosa (Fig. 1 B). Because of

this, the diameter of the capillary network on the surface of the connective tissue papillae beneath the mucosal epithelium was measured. The thickness of capillaries was about 0.7 times thinner in the DM than in the N group. A previous study reported that hyperglycemia causes diabetic microangiopathy in the capillaries in the lingual gingiva of the mandibular first molar¹ in GK rats. In addition, the proliferation of the vascular endothelial cells was suppressed when placed in a media containing a high glucose content *in vitro*.¹² Because of this, we reason that hyperglycemia suppressed the proliferation of the vascular endothelial cells and caused the diabetic microangiopathy, thereby causing a thinning of the capillaries of the palatine mucosa in our DM rats. A previous study showed that the diameter of the capillaries in the palatal gingiva of the maxillary first molar is about 0.5 times thinner in the DM group than in N rats.¹ It was also reported that the diameter of the capillaries in the lingual gingiva of the mandibular first molar was thinner in the DM than in the N group.³ Therefore, we think that hyperglycemia caused the diabetic microangiopathy, regardless of the region of the oral mucosa.

Based on our results we concluded that in DM rats, hyperglycemia caused hypertrophy of the keratinized and granular layers in the mucosal epithelium, atrophy of the connective tissue beneath the mucosal epithelium, and diabetic microangiopathy in the capillaries.

This study was presented at the 537th Meeting of the Osaka Odontological Society (Hirakata, Japan) on February 16, 2013. We would like to thank the staff of the facilities of Osaka Dental University for their support with the animal experiments and image processing. We also wish to express our

sincere gratitude to Akimichi Takemura, Associate Professor of the Department of Anatomy, Osaka Dental University, for his valuable guidance and criticism. We are indebted to the staff of the Department of Anatomy for their advice and encouragement.

REFERENCES

1. Yasuda K, Uemura M, Suwa F. Morphological study of the palatal gingiva of the maxillary first molar in the type 2 diabetes mellitus model rat. *Okajimas Fol Anat Jpn* 2011 ; **88** : 65–74.
2. Hata Y, Suwa F, Imai H. Histological study of gingival epithelium in a type II diabetes mellitus rat model. *J Osaka Dent Univ* 2004 ; **38** : 23–29.
3. Hata Y, Suwa F, Imai H, Takemura A, Ueda M. Microvasculature of the sub-sulcus epithelium in type 2 diabetic rat. *The Preliminary Program for IADR/AADR/CADR 82nd General Session 2004* ; Program No.2595.
4. Kanemura N, Suwa F, Ueda M. Morphological study of gingival connective tissue papillae in type II diabetes model rats. *J Osaka Dent Univ* 2007 ; **41** : 7–14.
5. Goto Y, Kakizaki M. The spontaneous-diabetes rat : A model of noninsulin dependent diabetes mellitus. *Proc Jpn Acad* 1981 ; **57** : 381–384.
6. Bergmeyer HU, ed. *Methods of enzymatic analysis*. New York and London : Academic Press, 1963 : 117–123.
7. Hirata M, Takanashi N, Oka M, Tsukada Y. Application of unsensitized soap-free latex to a new assay principle for HbA1c and its evaluation. *Japanese Journal of Medicine and Pharmaceutical Science* 1995 ; **34** : 125–136. (Japanese)
8. Sandler S, Karo W. *Polymer syntheses Vol.1 2nd ed*. Boston : Academic Press : 323–324.
9. Spravchikov N, Sizyakov G, Gartsbein M, Accili D, Tennenbaum T, Wertheimer E. Glucose effects on skin keratinocytes : implications for diabetes skin complications. *Diabetes* 2001 ; **50** : 1627–1635.
10. Tazawa K. Effects of high glucose concentration on cell proliferation, *in vitro* wound healing and IL-1 α production by the EGF-stimulated oral epithelial cell line, Ca9–22. *Nihon Univ Dent J* 2002 ; **76** : 25–30. (Japanese)
11. Hehenberger K, Hansson A, Heilborn J, Abdelhalim S, Östenson C, Brismar K. Impaired proliferation and increased L-lactate production of dermal fibroblasts in the GK-rat, a spontaneous model of non-insulin dependent diabetes mellitus. *Wound Rep Reg* 1999 ; **7** : 65–71.
12. Nelson DM, Curran EM. High glucose levels decrease proliferation of cultured human fetal cells from placenta. *Am J Obstet Gynecol* 1989 ; **161** : 1553–1558.